

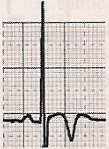
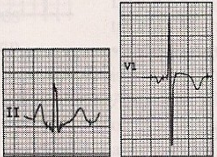
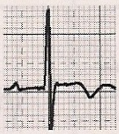


ST Depression

An athlete with any visually appreciated ST depression $>0.5\text{mm}$ below the PR isoelectric line occurring between the J-junction and beginning of the T wave $>0.5\text{mm}$ in any of lateral leads (I, AVL, V5, V6) and $>1\text{mm}$ in any lead should be sent for further evaluation.

Further evaluation for an athlete found to have RAA or LAA should include a more detailed history, physical examination, and a full resting echocardiogram. This study should include standard measurement of chamber size, wall thickness, and vascular function. In addition, it is valuable to estimate left and right ventricular as well as left atrial volumes using the Simpson rule Measurement of diastolic function including the tissue Doppler of the lateral or medial mitral annulus can be particularly valuable for detecting subclinical cardiomyopathy.

ECG Abnormality	Criteria for further evaluation	Example
Q waves	$>3\text{ mm}$ in depth or $>40\text{ ms}$ duration in any lead except III, aVR, aVL and V1	
ST depression	$>0.5\text{ mm}$ below PR isoelectric line between J-junction and beginning of T waves in V4, V5, V6, I, aVL $>1\text{ mm}$ in any lead	
T wave inversion	$>1\text{ mm}$ in leads other than III, aVR and V1 (except V2 and V3 in women <25 years)	
Atrial abnormalities	Right: P wave amplitude $>2.5\text{ mm}$ Left: i) Negative portion of P wave in V1, V2 of $>40\text{ ms}$ duration and 1 mm in depth; or ii) total P wave duration $>120\text{ ms}$	
Right ventricular hypertrophy	>30 years: i) R wave $>7\text{ mm}$ in V1; or ii) R/S ratio >1 in V1; or iii) sum of R wave in V1 and S wave in V5 or V6 $>10.5\text{ mm}$ <30 years: above plus right atrial enlargement, T wave inversion in V2, V3, or right axis deviation $>115^\circ$	

Cardiopulmonary exercise testing, although not necessary, may provide additional value in the differentiation of cardiomyopathy from athlete's heart if this is still not clear from imaging studies and ECG. In particularly borderline cases, a full 4-generation family pedigree and genetic testing may be able to rule in cardiomyopathy or channelopathy.

